

Surgical Treatment for Troublesome Mastoid Cavities: Canal Wall Reconstruction With Bony Obliteration Versus Subtotal Petrosectomy

*Glen Kemps, †Leontien Geven, ‡§Henricus Kunst, ‡Emmanuel Mylanus, ‡Jef Mulder, ‡Cris Lanting, and ‡||Ronald Pennings

*Department of Otorhinolaryngology, Isala Hospital, Zwolle; †Department of Otorhinolaryngology, ZGT Hospital, Almelo; ‡Department of Otorhinolaryngology, Radboudumc, Nijmegen; §Department of Otorhinolaryngology, MUMC+, Maastricht, The Netherlands; and ||Department of Otorhinolaryngology—Head and Neck Surgery, Universitair Ziekenhuis Brussel, Vrije Universiteit Brussel, Health Campus, Brussels, Belgium

Introduction: A chronically discharging modified radical mastoid cavity may require surgical intervention. We aim to explore two techniques.

Objective: To compare outcomes of subtotal petrosectomy (STP) and canal wall reconstruction with bony obliteration technique (CWR-BOT).

Study Design: Retrospective cohort study.

Setting: A tertiary referral center.

Patients: All patients with a chronically discharging mastoid cavity surgically treated at the Radboud University Medical Center by STP or CWR-BOT in 2015 to 2020, excluding patients with preoperative cholesteatoma.

Main Outcome Measures: Dry ear rate, audiometry, and rehabilitation.

Secondary Outcome measures: Healing time, number of postoperative visits, complications, cholesteatoma, and need for revision surgeries.

Results: Thirty-four (58%) patients underwent STP, and 25 (42%) CWR-BOT. A dry ear was established in 100% of patients (STP) and 87% (CWR-BOT). The air–bone gap (ABG) increased by 12 dB in STP, and decreased by 11 dB in CWR-BOT. Postoperative ABG of CWR-BOT patients was better when preoperative

computed tomography imaging showed aerated middle ear aeration. ABG improvement was higher when ossicular chain reconstruction took place. Mean follow-up time was 32.5 months (STP) versus 40.5 months (CWR-BOT). Healing time was 1.2 months (STP) versus 4.1 months (CWR-BOT). The number of postoperative visits was 2.5 (STP) versus 5 (CWR-BOT). Cholesteatoma was found in 15% (STP) versus 4% (CWR-BOT) of patients. Complication rate was 18% (STP) and 24% (CWR-BOT) with a need for revision in 21% (STP) and 8% (CWR-BOT), including revisions for cholesteatoma.

Conclusion: STP and CWR-BOT are excellent treatment options for obtaining a dry ear in patients with a chronically discharging mastoid cavity. This article outlines essential contributing factors in counseling patients when opting for one or the other. Magnetic resonance imaging with diffusion-weighted imaging follow-up should be conducted at 3 and 5 years postoperatively.

Key Words: Bony obliteration technique—Canal wall reconstruction—Draining cavity—Subtotal petrosectomy—Troublesome mastoid cavity.

Otol Neurotol 45:273–280, 2024.

INTRODUCTION

A chronically discharging modified radical mastoid cavity, unresponsive to conservative treatment, can significantly lower patients' quality of life and poses a challenge to any ear surgeon (1). Of patients with a mastoid cavity, 20 to 60% are reported to have persistent or intermittent drainage (2). A mastoid cavity can be defined as trouble-

some when the need for cleaning is considered to be too frequent, when there is persistent or recurrent otorrhea associated with inflammation or bacterial infection, or when water exposure is unavoidable (3). Surgical intervention can be indicated at this stage to create a dry and safe ear. The choice of surgery depends on many factors, e.g., the origin of the infection, aeration of the middle ear, preoperative hearing, and the patient's wishes (4). A small procedure to achieve these goals is a meatoplasty or canalplasty, which improves aeration of the cavity, facilitates more straightforward clearance of debris, and thereby lessens chances of microbial growth (5). Often, a meatoplasty is done as one element of a more elaborate cavity revision, which includes more invasive steps to the same effect, such as reduction of cavity size, removal of residual/regrown mastoid bone causing crevices, and/or closure of tympanic membrane

Address correspondence and reprint requests to Ronald Pennings, Ph.D., Department of Otorhinolaryngology—Head and Neck Surgery, Universitair Ziekenhuis Brussel, Vrije Universiteit Brussel, Health Campus, Brussels, Belgium; E-mail: Ronald.Pennings@radboudumc.nl

Glen Kemps and Leontien Geven share first co-authorship.

Conflicts of interest and source of funding: The authors disclose no conflicts of interest.

DOI: 10.1097/MAO.0000000000004109

perforations (6). Another option is to completely obliterate the ear canal, middle ear, and mastoid cavity by performing a subtotal petrosectomy (STP) (4,7). An STP is seen as a rigorously definite solution for a chronically draining cavity that requires frequent cleaning (4,7). Because of blind sac closure of the external ear canal, however, hearing can no longer be rehabilitated with conventional hearing aids. Depending on a patient's thresholds in audiometry, a bone conduction (BC) device, middle ear, or even cochlear implant may be an appropriate alternative.

Recently, interesting results have been achieved with posterior canal wall reconstruction combined with a bony obliteration technique of the mastoid (CWR-BOT) (1,3,8,9). In CWR-BOT, the external ear canal is reconstructed to restore anatomy. Moreover, an ossicular chain reconstruction (OCR) is possible and postoperative hearing rehabilitation with a conventional hearing aid remains an option. Although the published results of CWR-BOT are promising—surgically and in terms of quality of life (10–12)—revision surgery is indicated in 12% to 38% of cases, e.g., because of cholesteatoma formation and/or (partial) failure of the reconstruction (3,8). In this study, we analyze the results of CWR-BOT and STP for the treatment of chronically discharging mastoid cavities to aid clinicians in personalized counseling of their patients.

MATERIALS AND METHODS

This retrospective study was conducted according to the principles of the Declaration of Helsinki (3rd edition, 2015), in accordance with the Dutch Medical Research Involving Human Subjects Act, and in accordance with the standards of our local medical ethical committee.

Patients

All patients who underwent an STP or CWR-BOT because of a chronically discharging mastoid cavity, treated in the years 2015 to 2020 at our hospital, were included. Because the current study focuses on resolving symptoms of a troublesome cavity and not on outcomes related to the surgical indications of cholesteatoma, patients with preoperative cholesteatoma in their cavity were excluded.

Study Design

We performed a retrospective analysis of the medical records of all included patients. Primary outcome measures were dry ear rate, audiometric change, and hearing rehabilitation. Secondary outcome measures were healing time (defined as wound healing time in STP and epithelialization time in CWR-BOT), number of postoperative visits, complications, cholesteatoma formation, and need for revision surgeries. Patient demographics and preoperative computed tomography (CT) scans were also reviewed.

Audiometry

All audiometry was performed according to the latest standards with calibrated instruments. Measurements included standard pure-tone audiometry for air conduction (AC) and BC thresholds (0.25–8 kHz). The pure-tone

average (PTA) was calculated as the average of the measured thresholds at 0.5, 1, 2, and 3 kHz ($PTA_{(0.5,1,2,3kHz)}$). When thresholds at 3 kHz were not assessed, the average threshold of 2 and 4 kHz was used. The air–bone gap (ABG) was calculated as the difference between $PTA_{(0.5,1,2,3kHz)}$ of AC and BC.

Surgical Technique

STP was performed as described by Prasad et al. (4). After blind sac closure of the external ear canal, skin is meticulously removed from the cavity to prevent residual disease. After additional extensive exenteration of all accessible mastoid air cells, the cavity is filled with abdominal fat.

Our CWR-BOT technique resembles the technique described by Vercruyse et al. (8) After a wide postauricular incision and formation of a musculoperiosteal flap, cortical bone chips, and/or bone dust, cartilage and/or temporal muscle fascia is harvested. Healthy bone dust is harvested with a large cutting burr and then mixed with rifampicin. All epithelial lining and other pathological tissues are removed to achieve a clean and smooth radical cavity. The difference with the technique of Vercruyse et al. is that the nonpathological tympanic membrane remnants are left in place to reconstruct a new drum with cartilage when necessary. According to the surgeon's preference, the posterior canal wall is reconstructed with bone chips, large pieces of conchal cartilage, or temporalis fascia. No artificial bone cement is used. Next, the paratympanic space and mastoid are completely filled with bone dust mixed with rifampicin. If the canal is reconstructed with cartilage, it is (partially) covered with healthy skin remnants. In some cases, a midtemporal flap is used, as described by Yung et al. (6) An OCR is performed when possible, depending on the aeration (height) of the middle ear and mobility of the stapes and/or footplate. A ribbon gauze with Terra-Cortril ointment (Pfizer, New York) is placed in the external ear canal at the end of the procedure. This gauze is changed in the outpatient clinic, with a frequency and timing depending on the reconstruction (if less intact skin could be spared, the gauze stays in situ for longer) and epithelialization rate. All patients receive antibiotics intraoperatively (cefazoline) and postoperatively when the mastoid cavity is severely infected (based on preoperative cultures).

Postoperative Evaluation

The Clavien-Dindo complication classification system was used for assessing complication grades (13). Postoperative magnetic resonance imaging with diffusion-weighted imaging (MRI-DWI) was planned for patients of both groups 1 year after surgery, although many were postponed during the peak of the COVID pandemic. In some patients, MRI results were equivocal for cholesteatoma, and more were planned between 1 and 3 years after the first, according to size, suspicion, and location of the lesion. Scans up to the end of 2022 were included in the results of this study.

Statistical Analysis

The study data analysis was carried out using SPSS software (version 27.0). Independent or dependent sample *t* test

and chi-squared analysis were used when applicable. A *p* value of 0.05 was considered statistically significant.

RESULTS

Patient Demographics

Between 2015 and 2020, 34 patients underwent STP and 25 patients CWR-BOT for their discharging mastoid cavity and were included in this study. Mean age was 51 years (19–89 yrs). Patient demographics are listed in Table 1. Apart from preoperative AC, preoperative BC, and the number of previous surgeries, no significant differences were found between both groups. In the CWR-BOT group, two patients (8%) were lost for follow-up, and two (8%) died of an unrelated cause. Some postoperative data could still be used in the analysis of the latter two. In the STP group, one patient (3%) was lost for follow-up, and one (3%) had died of an unrelated illness.

Surgical Techniques in CWR-BOT

Depending on surgeon preference in CWR-BOT patients, different autologous materials were used to reconstruct the posterior canal wall (Table 2). During surgery, the surgeon assessed whether OCR was necessary, feasible, and worthwhile, based on available middle ear space and mobility of the remaining ossicular chain and footplate. Thirteen patients (52%) received reconstruction, either through a prosthesis or by directly connecting the ear drum with the stapes suprastructure with a piece of cartilage. In one patient (8%), the prosthesis extruded within several months after surgery.

Perioperative Results

All patients in the STP group and 87% of the CWR-BOT group obtained a dry ear after surgery (Table 3, *p* = 0.03). There was a significant difference between mean healing time (1.2 vs. 4.1 months, *p* < 0.001) and mean number of postoperative visits (2.5 vs. 5.0, *p* < 0.001) between the STP and CWR-BOT group, respectively. This is reflected in practice as patients after STP having to come by the outpatient clinic only once or twice to remove sutures and check for complications, whereas in contrast, CWR-BOT patients are seen more frequently and for longer to have

TABLE 2. Techniques in CWR-BOT

		Patients (N = 25)
CWR with cartilage		14 (56%)
CWR with bone chips		10 (40%)
CWR with fascia		1 (4%)
Midtemporal flap		5 (20%)
OCR	Yes	13 (52%)
	No	12 (48%)

CWR-BOT indicates canal wall reconstruction with bony obliteration technique; OCR, ossicular chain reconstruction.

their reconstructed ear canal cleaned of debris and for the administration of topical medication.

Audiometric Results

Audiometric results are shown in Table 4 and Fig. 1. Preoperatively, BC thresholds of patients planned for CWR-BOT were lower (21 dB, SD 13) than the ones in the STP group (41 dB, SD 30; *p* = 0.002). The same was true for AC thresholds (CWR-BOT: 57 dB, SD 20 vs. STP: 75 dB, SD 24; *p* = 0.004). The preoperative ABG was not significantly different (CWR-BOT: 36 dB, SD 16; STP: 34 dB, SD 15; *p* > 0.05); however, the mean postoperative ABG was (CWR-BOT: 26 dB, SD 11; vs. STP: 44 dB, SD 20; *p* = 0.001). There was no deterioration of BC thresholds related to surgery when comparing preoperative and postoperative levels in a paired sample *t* test (CWR-BOT: *p* = 0.096 and STP: *p* = 0.267). The postoperative ABG in the CWR-BOT group was significantly lower when a preoperative CT scan showed aeration of the middle ear. This was the only significant finding in the evaluation of preoperative patient demographics (Table 1) that had impact on postoperative audiometric outcomes (aerated middle ear: 22 dB, SD 10 [N = 12] vs. non-aerated middle ear: 34 dB, SD 10 [N = 6]; *p* = 0.03). The postoperative audiometric results of 13 CWR-BOT patients that underwent OCR are shown in Table 5. A mean improvement in ABG of 16.2 dB was seen after OCR, and this change was significantly larger compared with nine CWR-BOT patients in which no OCR was performed and who had postoperative audiometric test results available (−2.6 dB, *p* < 0.05).

TABLE 1. Patient demographics

	STP (N = 34)	CWR-BOT (N = 25)	<i>p</i>
Mean age (SD)	54.1 (SD 16.1)	47.2 (SD 13.2)	>0.05
Male	20 (59%)	11 (44%)	>0.05
Side	18 right (52.9%)	10 right (40%)	>0.05
Follow-up (mo)	32.5 (range, 8–61)	40.5 (range, 18–62)	>0.05
Number of previous surgeries (median)	3.0 (range, 1–14)	2.0 (range, 1–6)	0.038
Middle ear on preoperative CT	Aerated	9	>0.05
	Non-aerated	20	>0.05
	Not available	5	>0.05
Mean preoperative PTA _(0.5,1,2,3kHz) BC (SD)	40.6 dB (30.0) (n = 32)	20.8 dB (13.1) (n = 24)	0.002
Mean preoperative PTA _(0.5,1,2,3kHz) AC (SD)	74.9 dB (23.6) (n = 32)	56.8 dB (20.3) (n = 24)	0.004
Mean preoperative PTA _(0.5,1,2,3kHz) ABG (SD)	34.3 dB (14.6) (n = 32)	36.1 dB (15.7) (n = 24)	>0.05

Bold indicates a significant difference.

ABG, air–bone gap; AC, air conduction; BC, bone conduction; CT, computed tomography; CWR-BOT, canal wall reconstruction with bony obliteration technique; PTA, pure-tone average; SD, standard deviation; STP, subtotal petrosectomy cohort.

TABLE 3. *Surgical outcomes*

	STP	CWR-BOT	<i>p</i>
Early postoperative phase			
Dry ear*	31 (100%)	20 (87%)	0.03
Healing time (mo)	1.2 (SD 0.4)	4.1 (SD 3.5)	<0.001
Outpatient clinic visits (N)	2.5 (range, 0–9)	5 (range, 2–20)	<0.001
Epithelialization time (mo)	–	4.4 (SD 3.4)	
Complications (N)			
Grade I	0 (0%)	3 (12%)	
Grade II	4 (12%)	2 (8%)	
Grade IIIb	2 (6%)	2 (8%)	
Total	6 (18%)	7 (28%)	
Follow-up			
Cholesteatoma			
Negative	22 (65%)	21 (84%)	>0.05
Positive	5 (15%)	1 (4%)	
Equivocal	4 (12%)	1 (4%)	
Unknown	3 (9%)	2 (8%)	
Number of MRIs (SD)	1.4 (0.72)	1.4 (0.9)	>0.05
MRI follow-up time (mo)	38 (SD 22)	34 (SD 25)	>0.05

Bold indicates a significant difference.

CWR-BOT indicates canal wall reconstruction with bony obliteration technique; STP, subtotal petrosectomy cohort.

*When assessed.

Audiometric Rehabilitation

Methods of hearing rehabilitation are shown in Table 6. Of the STP group, the majority use rehabilitation in the form of a BC device (BCD), contralateral routing of signal (CROS) aid, or middle ear implant (65%).

After CWR-BOT, four patients (16%) had a preoperative PTA_(0.5,1,2,3kHz) above 35 dB and a postoperative PTA_(0.5,1,2,3kHz) below this threshold, placing them in a category that might not require hearing rehabilitation. Two patients (8%) wore a hearing aid preoperatively and did not need it after surgery. The other two did not wear an aid preoperatively because of recurrent infections. Two other patients (8%) switched from wearing a BCD preoperatively to a conventional hearing aid postoperatively. Three other patients (12%) went from wearing nothing or a conventional aid preoperatively to wearing a BCD implanted during or shortly after their reconstruction. Of the three patients (12%) in whom the reconstruction failed, one patient used a BCD and the other 2 did not wear a hearing aid.

Postoperative Imaging and Cholesteatoma

Mean radiological follow-up time for patients was 36 months (SD 23). When cholesteatoma was found, mean radiological detection time over both groups was 40 months (range, 10–80), 42 for STP, and 28 for CWR-BOT. The

results of postoperative imaging are shown in Table 3. In one case in the STP group (3%), an MRI was not possible because of the presence of an active middle ear implant. Clinically, however, no symptoms pointing to cholesteatoma formation were found. One patient (3%) died before an MRI had been performed, and one patient (3%) was lost to follow-up. In five patients (15%), cholesteatoma was found. All five were planned for revision surgery, three of which were done within the scope of this study. In two of these cases, cholesteatoma was found close to the blind sac closure, and in one case, it was found close to the stylomastoid foramen. Further MRI follow-up was either negative or not yet performed. In the CWR-BOT group, two patients (8%) were lost to follow-up. One patient (4%) developed cholesteatoma after conversion to an STP due to failure of the reconstruction.

Complications

The number of postoperative complications and related Clavien-Dindo grades are shown in Table 3. In the STP group, four patients (12%) developed a postoperative bacterial infection, which could be treated by either local and oral antibiotics (N = 3) or intravenous antibiotics (N = 1). These complications were classified as grade II. In one patient (3%), the abdominal fat got infected, which required revision surgery (grade IIIb). One patient (3%) had a postoperative hemorrhage from the abdominal wound, requiring revision surgery (grade IIIb).

In the CWR-BOT group, two patients (8%) with a postoperative infection were treated with local antibiotics and antimycotics (grade II). We believe it prudent to perform a preoperative culture swab to start aimed treatment in cases where such infections occur. There were two patients (8%) in whom the reconstruction failed within the first few months after surgery. In one of them, this eventually resulted in a dry radical cavity (grade I), whereas the other was converted to an STP (grade IIIb), which as mentioned in the previous section was later found to contain inclusion cholesteatoma at MRI follow-up, for which surgery is planned. A partial midcanal stenosis formed in one patient (4%), requiring frequent cleaning (grade I). In another patient (4%), the midtemporal flap used to cover the bone dust became necrotic, and revision surgery was considered, but the patient preferred conservative management. The ear is slowly forming into a dry radical cavity (grade I). Lastly, one patient (4%) developed a cholesterol granuloma within the obliterated cavity, requiring revision surgery (grade

TABLE 4. *Audiometric outcomes*

	STP			CWR-BOT		
	Preoperative (N = 32)	Postoperative (N = 23)	<i>p</i>	Preoperative (N = 24)	Postoperative (N = 22)	<i>p</i>
Mean BC PTA _(0.5,1,2,3kHz) (SD; min–max)	41 dB (30; 9–120)	47 dB (34; 4–120)	0.3	21 dB (13; 4–53)	20 dB (14; 4–53)	0.1
Mean AC PTA _(0.5,1,2,3kHz) (SD; min–max)	75 dB (24; 36–120)	90 dB (21; 49–120)	<0.001	57 dB (20; 20–103)	45 dB (20; 20–93)	0.005
Mean ABG (SD; min–max)	34 dB (15; 0–56)	43 dB (20; 0–78)	<0.001	36 dB (16; 13–64)	26 dB (11; 10–51)	0.005
Mean ABG change (SD; min–max)		12 dB (12; –4 to 37)			–11 dB (16; –42 to 28)	<0.001

Bold indicates a significant difference.

ABG indicates air–bone gap; AC, air conduction; BC, bone conduction; CWR-BOT, canal wall reconstruction with bony obliteration technique; PTA, pure-tone average; STP, subtotal petrosectomy cohort.

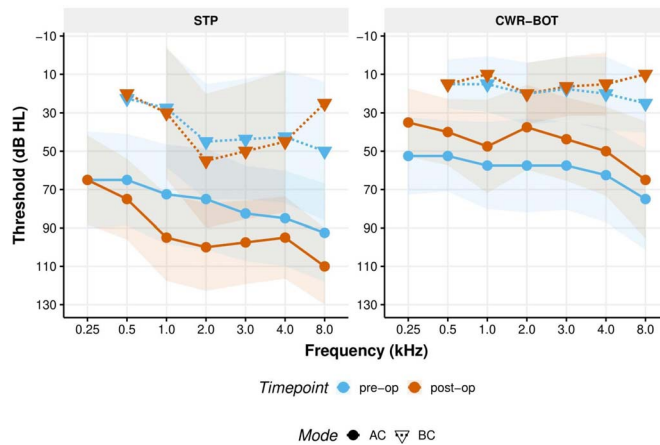


FIG. 1. Comparison of pre- and postoperative AC (○ and solid line) and BC (▼ and dashed line) thresholds for two types of surgeries: *left panel*, STP, with preoperative thresholds shown in blue and postoperative thresholds in orange; *right panel*, CWR-BOT, with both pre- and postoperative thresholds. AC indicates air conduction; BC, bone conduction; CWR-BOT, canal wall reconstruction with bony obliteration technique; STP, subtotal petrosectomy.

IIIb). These numbers of complications were considered too small for statistical comparison.

DISCUSSION

According to our study, the postoperative dry ear rate is high in patients after both STP and CWR-BOT, with it being slightly higher in the former. On average, hearing improves after CWR-BOT and decreases after STP. Postoperative ABG of CWR-BOT patients is better when a preoperative CT shows an aerated middle ear and ABG improves more when an OCR is done.

Healing time is faster in STP than in CWR-BOT. Cholesteatoma rates are higher after STP than CWR-BOT. Complication rates are higher in CWR-BOT than in STP. Revision surgery is more often indicated after STP than CWR-BOT. Mean detection time for cholesteatoma with MRI-DWI was 28 and 42 months after CWR-BOT and STP, respectively.

Audiometric Outcomes

In CWR-BOT patients, the ABG improved postoperatively by roughly 11 dB, whereas hearing decreased by around 12 dB in the STP group. The mean postoperative ABG was 26 dB after CWR-BOT and 43 dB after STP. In the literature, authors have presented similar improvements after CWR-BOT. Some studies report higher ABG improvements (1,6,10) and some lower (8,9,14), which might be partly explained by a different ABG preoperatively. Among the authors who reported a lower postoperative ABG, the majority had performed a second-stage middle ear surgery. However, details about the indications and techniques used for this surgery were not thoroughly explained. Mendlovic et al. (15) conducted a review that included studies reporting a mean postoperative ABG ranging from 23 to 30 dB. All studies consistently demonstrated improved hearing after CWR-BOT, vital information to share with patients during counseling. For surgeons, CT imaging that reveals middle ear aeration appears to be a

valuable parameter for predicting the postoperative ABG and therefore counseling patients preoperatively. At first glance, the results regarding OCR in CWR-BOT patients seem contradictory, with the ABG improving significantly more in patients with OCR than without, but with similar postoperative AC thresholds and ABG. One would expect the postoperative AC thresholds and ABG to be higher in unreconstructed patients. An explanation may be that during surgery, the surgeon assessed with accuracy which ossicular chain needs reconstruction and which does not. An OCR may be judged to be unfeasible because of lack of room, or it might not be useful because of a fixated stapes or footplate. However, it could also be decided in a patient with a relatively low preoperative ABG, for example, to not touch the ossicular chain or indeed not even fully expose the middle ear. An operating note may not explicitly mention this, but only that an OCR has not taken place. When looking at the details of CWR-BOT patients with OCR in Table 5, some points are worth mentioning. First, not all patients had an aerated middle ear on preoperative imaging. Second, reconstruction was mostly done with a total ossicular replacement prosthesis (TORP). Lastly, reconstruction by cartilage directly on the stapes did not yield very good results in terms of postoperative ABG when comparing these small numbers.

Audiometric Rehabilitation

Fortunately in both groups, BC thresholds did not change after surgery, making rehabilitation possible. As indicated in Table 5, the majority of patients in this study used hearing aids, regardless of the type of surgery they received.

The audiometric improvement achieved through CWR-BOT theoretically means that a patient may no longer require a hearing aid for their affected ear, or that an ear that was previously unaidable can now be assisted. In our study cohort, four patients experienced the former benefit, whereas none experienced the latter. Two patients demonstrated another advantage of the operation, as they were able to wear a conventional hearing aid with less risk of

TABLE 5. Data of CWR-BOT patients with OCR

Patient	Preoperative CT Middle Ear Aeration	OCR	Preoperative AC PTA (0.5,1,2,3kHz) (dB)	Preoperative BC PTA (0.5,1,2,3kHz) (dB)	Preoperative ABG (dB)	Postoperative AC PTA (0.5,1,2,3kHz) (dB)	Postoperative BC PTA (0.5,1,2,3kHz) (dB)	Postoperative ABG (dB)	ABG Change (dB)
1	Yes	TORP	80.0	28.1	51.9	36.3	26.3	10.0	-41.9
2	Yes	TORP	32.5	4.4	28.1	25.6	10.6	15.0	-13.1
3	Yes	TORP	75.0	15.6	59.4	28.8	6.3	22.5	-36.9
4	Yes	TORP	67.5	20.6	46.9	28.8	10.0	18.8	-28.1
5	No	Cartilage	38.1	11.3	26.9	28.1	8.8	19.4	-7.5
6	No	Cartilage	62.5	28.1	34.4	58.8	25.0	33.8	-0.6
7	Yes	Cartilage	55.6	19.4	36.3	60.6	23.1	37.5	1.3
8	Yes	TORP	82.5	41.3	41.3	53.8	32.5	21.3	-20.0
9	No	TORP	103.1	39.4	63.8	92.5	41.9	50.6	-13.1
10	Yes	PORP	70.6	52.5	18.1	65.0	12.5	12.5	-5.6
11	No CT	TORP	71.9	23.1	48.8	40.0	20.6	19.4	-29.4
12	Yes	TORP	61.9	8.8	53.1	40.6	10.0	30.6	-22.5
13	Yes	TORP	31.9	16.3	16.3	40.0	16.3	23.8	7.5
Mean	-	-	64.1	23.7	40.4	46.1	21.8	24.2	16.2

Bold indicates a significant difference.

ABG indicates air-bone gap; BC, bone conduction; CT, computed tomography; CWR-BOT, canal wall reconstruction with bony obliteration technique; OCR, ossicular chain reconstruction; PORP, partial ossicular replacement prosthesis; PTA, pure-tone average; TORP, total ossicular replacement prosthesis.

infection. Three patients transitioned from using a conventional to a BC aid because of concerns about infection in the operated ear. Limited data exist in the literature regarding hearing aid use after CWR-BOT. Vercruysse et al. (8) report that 34% of patients used either a conventional hearing aid or a BCD after surgery.

In the STP group, the majority of patients preferred a BCD to aid the ipsilateral ear. Reasons for not using a device included severe hearing loss on that side or patients having become accustomed to not hearing with that ear because of recurrent infections preoperatively.

Cholesteatoma

In both techniques, because of risk of residual, recurrent, or inclusion cholesteatoma, follow-up is prudent. As recidivism is often clinically silent for a long time, it is necessary to do this through MRI-DWI scanning (7). However, the timing of this follow-up remains controversial (6,8,16). In our center, radiological follow-up after cholesteatoma surgery comprises a scan 1, 3, and 5 years postsurgery. The current patient population is different, however, in that patients with cholesteatoma as indication for surgery were excluded. Therefore, MRI timing and frequency was not standardized for this group, causing it to vary between surgeons. Moreover, during the COVID pandemic, a lack of radiological resources added to this considerable variation in follow-up time. In the literature, several studies have assessed cholesteatoma rates in CWR-BOT patients and found ranges from 0 to 21% (9,12,14,15,17-19). The relatively low percentage of the current study (4% cholesteatoma, with 12% unknown or still equivocal) may be because most authors have included patients with known preoperative cholesteatoma or had longer follow-up periods. For STP, residual cholesteatoma rates vary from 1.1 to 17%, with many in the form of inclusion epithelium near the atresia site, a notorious localization (4,20). The relatively high rate of the current study (15%) might be explained by the fact that our center is an otological teaching hospital and indicates that formation of the blind sac closure has a significant learning curve. Similarly to the present study's findings, in the literature, the average time until radiological cholesteatoma detection has been found to be 43 to 46 months (14,20), which could indicate that long-term follow-up of at least this length is advisable. Prasad et al. (4) recommends an even longer period of up to 10 years in patients after STP. Vercruysse et al. (8) advise 5 years of radiological follow-up of CWR-BOT patients, and yearly otoscopically after that until 10 years postoperatively, then once every 3 years onward. Taking all of the mentioned into account and considering the mean detection times found in the highly selected patient group of the current, we suggest performing an MRI after 1.5 and 5 years after CWR-BOT and 3 and 5 years after STP. The first scan in this protocol would then be several months earlier than our mean detection time, and the second one would find any later formed cholesteatoma.

Complications

The total complication rate in our patient cohort was 18% in the STP group and 28% in the CWR-BOT group, with rates of revision surgery, including for cholesteatoma,

TABLE 6. Hearing rehabilitation

	STP (N = 24)		CWR-BOT (N = 25)	
	Preoperative	Postoperative	Preoperative	Postoperative
Conventional hearing aid	0 (0%)	0 (0%)	2 (8%)	2 (8%)
Bone conductive device	12 (35%)	20 (59%)	2 (8%)	4 (16%)
No hearing aid	22 (65%)	10 (29%)	17 (68%)	15 (60%)
Middle ear implant	0 (0%)	1 (3%)	0 (0%)	0 (0%)
CROS hearing aid	0 (0%)	1 (3%)	0 (0%)	0 (0%)
Unknown	0 (0%)	2 (6%)	4 (16%)	4 (16%)

CWR-BOT indicates canal wall reconstruction with bony obliteration technique; STP, subtotal petrosectomy cohort.

of 21% and 8%, respectively. Previous studies report complication rates in CWR-BOT patients of 9 to 36% (1,9), and a need for revision surgery in 9 to 21% of patients, including for recurrent and residual cholesteatoma (1,3,6,9,17). Accurate comparisons between studies are difficult because of different definitions of complications. Cox et al. (1), for instance, report postoperative middle ear effusion or atelectasis of the middle ear as a complication, resulting in a relatively high complication rate (36%). In the current study, without otorrhea, this would be considered a safe and stable situation. Most frequently described complications in the literature were postauricular wound infection, external canal stenosis, myringitis, cholesterol granuloma, obliteration material reabsorption, and transient or permanent facial nerve palsy (1,3,21).

In the literature, STP complication rates vary between 5.6 and 32% and revision rates between 7 and 22% (4,20,22). Geerse et al. (20), also using the Clavien-Dindo grading system, report a 32% complication rate. Their cohort had a need for revision surgery in 9% of cases, excluding patients with cholesteatoma recurrence (9%). As in the current study, infection of the fat transplant or abdominal wound has been known to occur (4,20,22). On top of that, fistulas of the blind sac closure, insufficient Eustachian tube closure, and facial nerve function deterioration have been described (4,20).

Limitations

As in any retrospective study, limitations of this study are the occasional unavailability of data and the loss of follow-up of some patients. Furthermore, preoperative differences between groups might be of influence for their postoperative outcomes. However, it is challenging to avoid some characteristics when comparing these patients, such as BC thresholds and the number of previous surgeries, as they naturally influence surgery preference. For example, STP would be the more obvious choice for a patient with a high BC threshold as then the hearing improvement strived for in CWR-BOT might not make much difference to total hearing, especially when the contralateral ear has (near-) normal hearing. Also, because of its reputation as a rigorous last resort to attain a dry ear, STP would be a logical choice in patients who have had more failed previous attempts. In addition, although patient age was not found to significantly influence healing or epithelialization after CWR-BOT in this study, it is logical to assume that younger patients with greater regenerative capacity would have a higher chance of successful reconstruction. Although data

on this is not known, there is a possibility they advised STP over CWR-BOT to older patients, which may have caused a selection bias. Another limitation is that, even though it is known in the literature and to the authors that insufficient external aeration might create an environment hospitable for infections or even cause midcanal stenosis, data pertaining to preoperative and postoperative external ear canal status was mostly lacking. Furthermore, data regarding the source localization of persistent or intermittent otorrhea, e.g., middle ear, cavity, or granulomatous tympanic membrane, were not known, despite those potentially being useful in decision-making. Lastly, besides the current evaluation, patient-reported outcome measures (e.g., quality of life) were unavailable. A thorough comparison between these groups would likely help aid clinician's decisions and is an interesting topic for future studies.

Recommendations and Future Prospects

It is recommended that a prospective, multicenter study be conducted on patients with chronically draining radical mastoid cavity to address the limitations of this retrospective study. Data regarding the reasons why STP or CWR-BOT is chosen, pre- and postoperative external ear aeration status, infection source localization, and quality of life should be added to its metrics.

CONCLUSION

Both STP and CWR-BOT are excellent treatment options for obtaining a dry ear in patients with a chronically discharging mastoid cavity. Preoperative middle ear aeration on CT, postoperative dry ear rate, mean follow-up time, healing time, number of postoperative visits, postoperative cholesteatoma rate, postoperative complication rate, revision surgery rate, and postoperative ABG are essential factors in counseling patients with regard to opting between CWR-BOT or STP as treatment for their chronically draining radical mastoid cavity. We recommend to perform MRI-DWI follow-up at 3 and 5 years after STP and 1.5 and 5 years after CWR-BOT.

REFERENCES

1. Cox MD, Dunlap QA, Trindade A, et al. Long-term outcomes after secondary mastoid obliteration. *Otol Neurotol* 2016;37:1358–65.
2. Saunders JE, Shoemaker DL, McElveen JT Jr. Reconstruction of the radical mastoid. *Am J Otol* 1992;13:465–9.

3. Geerse S, Ebbens FA, de Wolf MJ, et al. Successful obliteration of troublesome and chronically draining cavities. *J Laryngol Otol* 2017; 131:138–43.
4. Prasad SC, Roustan V, Piras G, et al. Subtotal petrosectomy: surgical technique, indications, outcomes, and comprehensive review of literature. *Laryngoscope* 2017;127:2833–42.
5. Memari F, Maleki Delarestaghi M, Mir P, et al. Meatoplasty in canal wall down surgery: our experience and literature review. *Iran J Otorhinolaryngol* 2017;29:11–7.
6. Yung M, Tassone P, Mousoulidis I, et al. Surgical management of troublesome mastoid cavities. *J Laryngol Otol* 2011;125:221–6.
7. Macielak RJ, Kull AJ, Carlson ML, et al. Disease recidivism after subtotal petrosectomy and ear canal closure. *Am J Otolaryngol* 2023; 44:103743.
8. Vercruyse JP, van Dinther JJ, De Foer B, et al. Long-term results of troublesome CWD cavity reconstruction by mastoid and epitympanic bony obliteration (CWR-BOT) in adults. *Otol Neurotol* 2016;37: 698–703.
9. van der Toom HFE, van der Schroeff MP, Molenaar TL, et al. Revision surgery for chronically discharging mastoid cavities: mastoid obliteration with canal wall reconstruction versus non-obliteration surgery. *Eur Arch Otorhinolaryngol* 2022;279:3881–9.
10. Weiss NM, Bächinger D, Botzen J, et al. Mastoid cavity obliteration leads to a clinically significant improvement in health-related quality of life. *Eur Arch Otorhinolaryngol* 2020;277:1637–43.
11. Uluyol S, Ugur O, Arslan IB, et al. Effects of cavity reconstruction on morbidity and quality of life after canal wall down tympanomastoidectomy. *Braz J Otorhinolaryngol* 2018;84:608–13.
12. Kurien G, Greeff K, Gomaa N, et al. Mastoidectomy and mastoid obliteration with autologous bone graft: a quality of life study. *J Otolaryngol Head Neck Surg* 2013;42:49.
13. Dindo D, Demartines N, Clavien PA. Classification of surgical complications: a new proposal with evaluation in a cohort of 6336 patients and results of a survey. *Ann Surg* 2004;240:205–13.
14. Geerse S, Bost TJM, Allagul S, et al. Hearing and hearing rehabilitation after obliteration of troublesome mastoid cavities. *Eur Arch Otorhinolaryngol* 2020;277:3307–13.
15. Mendlovic ML, Monroy Llaguno DA, Schobert Capetillo IH, et al. Mastoid obliteration and reconstruction techniques: a review of the literature. *J Otolaryngol* 2021;16:178–84.
16. Barbara M, Covelli E, Monini S, et al. Early non-EPI DW-MRI after cholesteatoma surgery. *Ear Nose Throat J* 2021;1455613211042946.
17. Alves RD, Cabral F Jr., Fonseca AC, et al. Mastoid obliteration with autologous bone in mastoidectomy canal wall down surgery: a literature overview. *Int Arch Otorhinolaryngol* 2016;20:76–83.
18. Sioshansi PC, Alyono JC, Blevins NH. Mastoid obliteration using autologous bone dust following canal wall down mastoidectomy. *Otol Neurotol* 2021;42:68–75.
19. van der Toom HFE, van der Schroeff MP, Metselaar M, et al. A retrospective analysis of hearing after cholesteatoma surgery: the bony obliteration tympanoplasty versus canal wall up and canal wall down without mastoid obliteration. *Eur Arch Otorhinolaryngol* 2022;279:5181–9.
20. Geerse S, de Haan RJ, Ebbens FA, et al. Surgical results and quality of life after subtotal petrosectomy. *Eur Arch Otorhinolaryngol* 2023;280:61–8.
21. Lee WS, Kim SH, Lee WS, et al. Canal wall reconstruction and mastoid obliteration in canal wall down tympanomastoidectomized patients. *Acta Otolaryngol* 2009;129:955–61.
22. Kraus M, Hassannia F, Bergin MJ, et al. Long-term outcomes from blind sac closure of the external Auditory Canal: our institutional experience in different pathologies. *J Int Adv Otol* 2020;16:58–62.